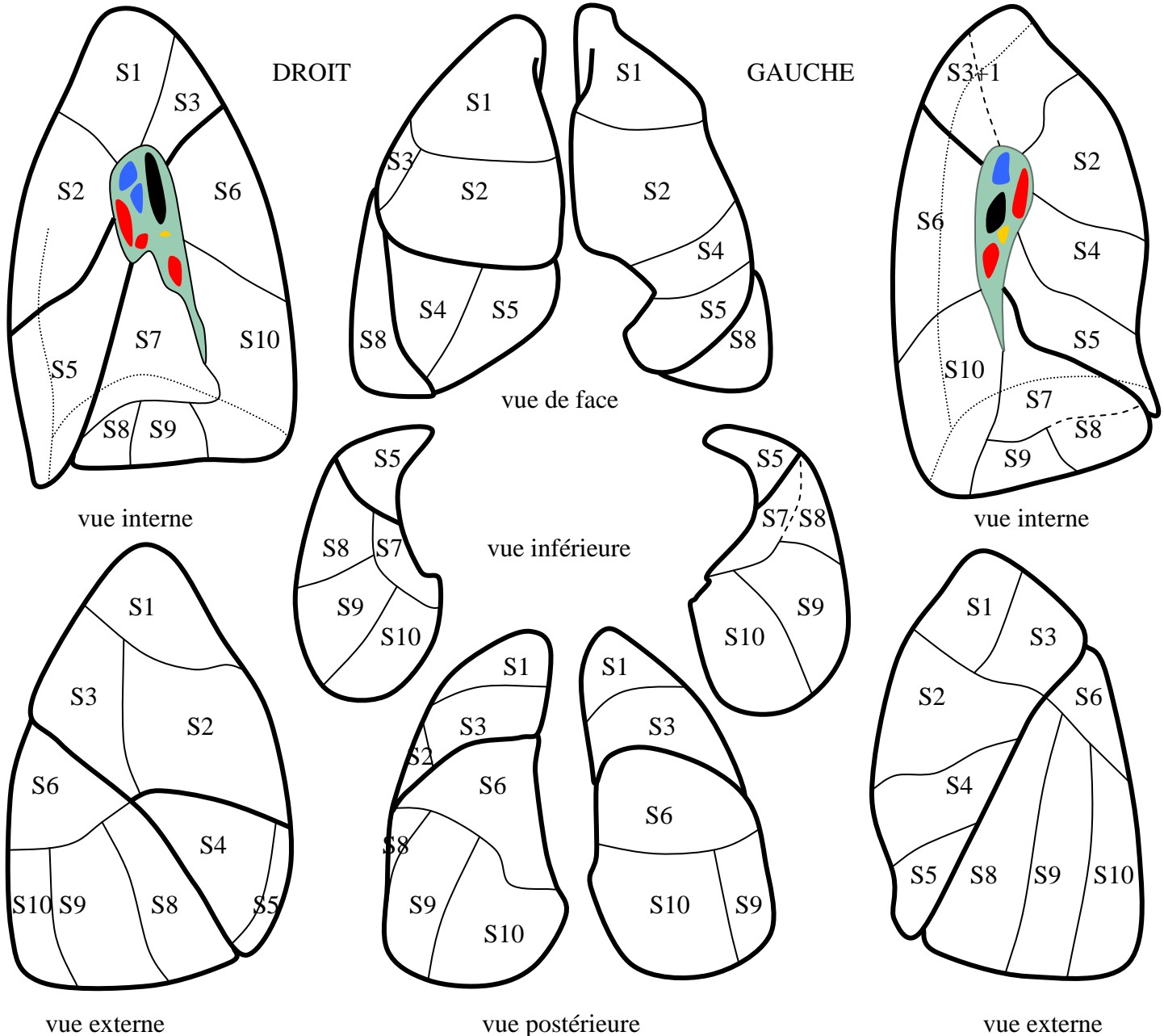


SEGMENTATION PULMONAIRE

Docteurs Marie-Pierre REVEL, Marc TORRENT

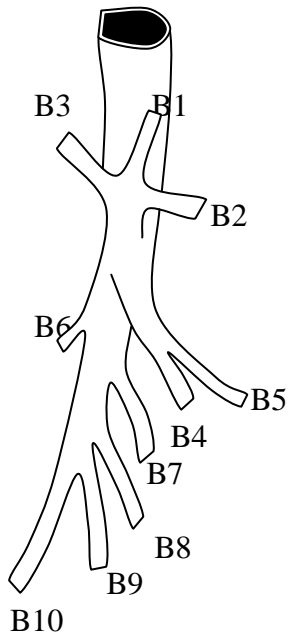
LES SEGMENTS PULMONAIRES :

LSD	Segments	Bronches	Artères	Veines	LSG (CULMEN)	Segments	Bronches	Artères	Veines
Apical	S1	B1	A1	V1	Apicodorsal	S1+3	B1+3	A1+3	V1+3
Ventral	S2	B2	A2	V2	Ventral	S2	B2	A2	V2
Dorsal	S3	B3	A3	V3					
LM					LINGULA				
Postéro externe	S4	B4	A4	V4	Supérieur	S4	B4	A4	V4
Antéro-interne	S5	B5	A5	V5	Inférieur	S5	B5	A5	V5
LID					LIG				
Apical	S6	B6	A6	V6	Apical	S6	B6	A6	V6
Paracardiaque	S7	B7	A7	V7	Antérobasal	S7+8	B7+8	A7+8	V7+8
Antérobasal	S8	B8	A8	V8					
Latérobasal	S9	B9	A9	V9	Latéral	S9	B9	A9	V9
Postérobasal	S10	B10	A10	V10	Postérieur	S10	B10	A10	V10

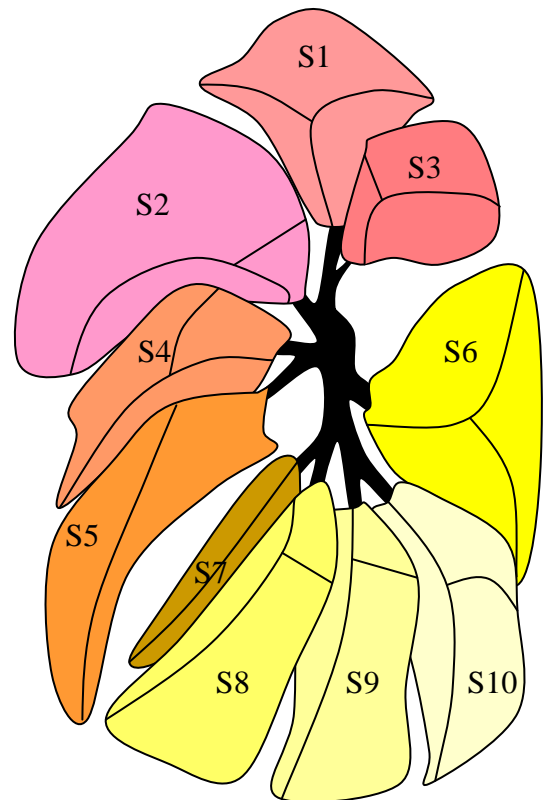
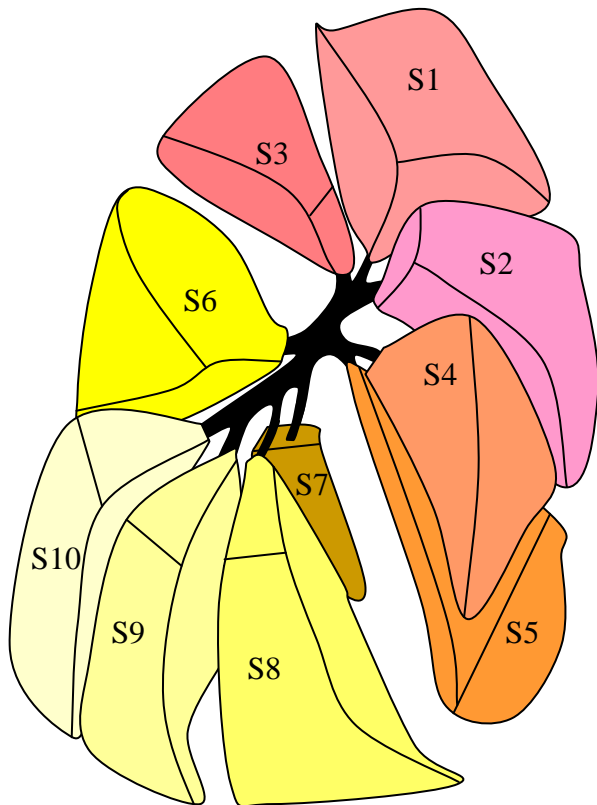
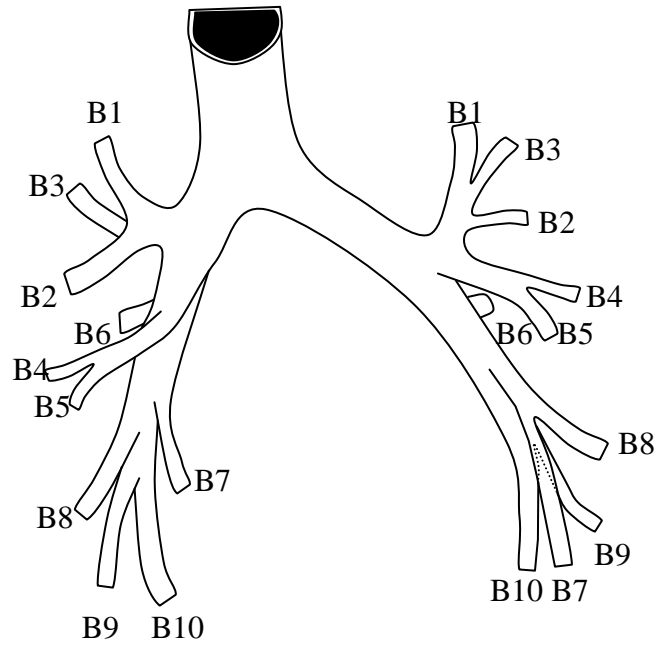


L'AXE BRONCHIQUE :

DROIT



GAUCHE

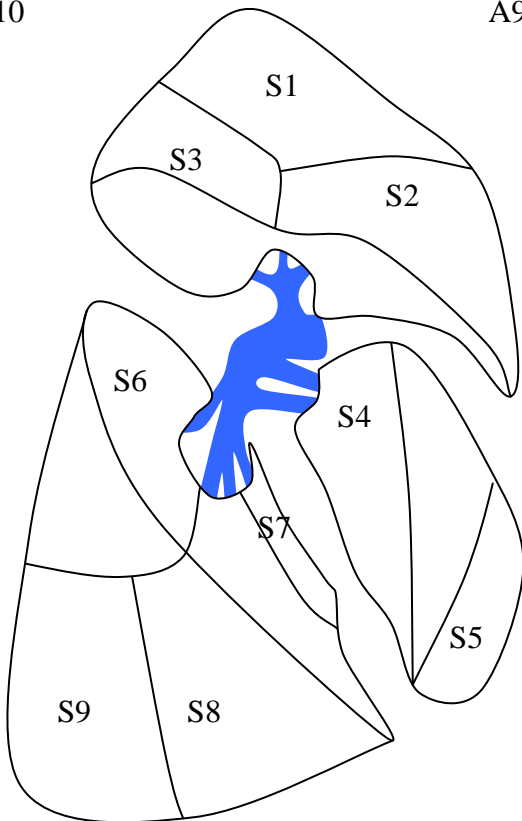
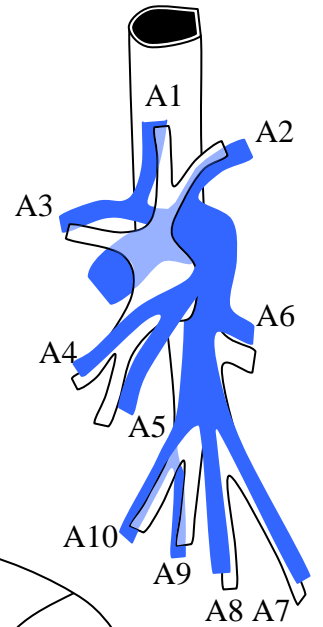
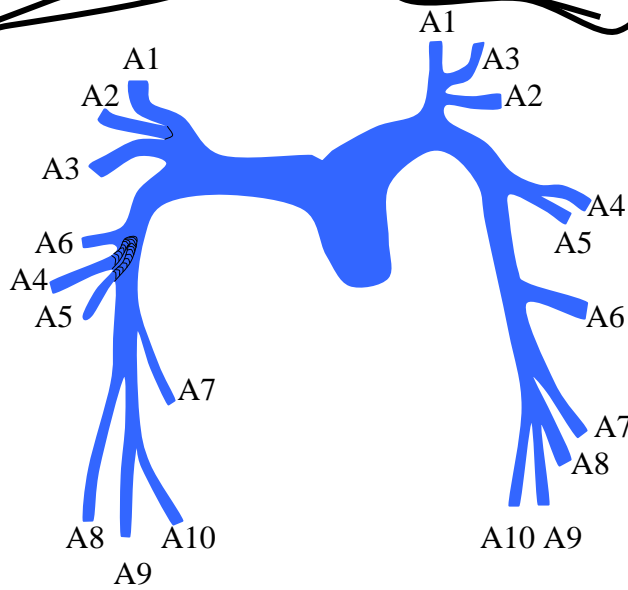
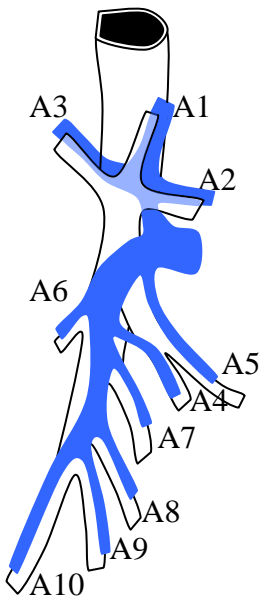
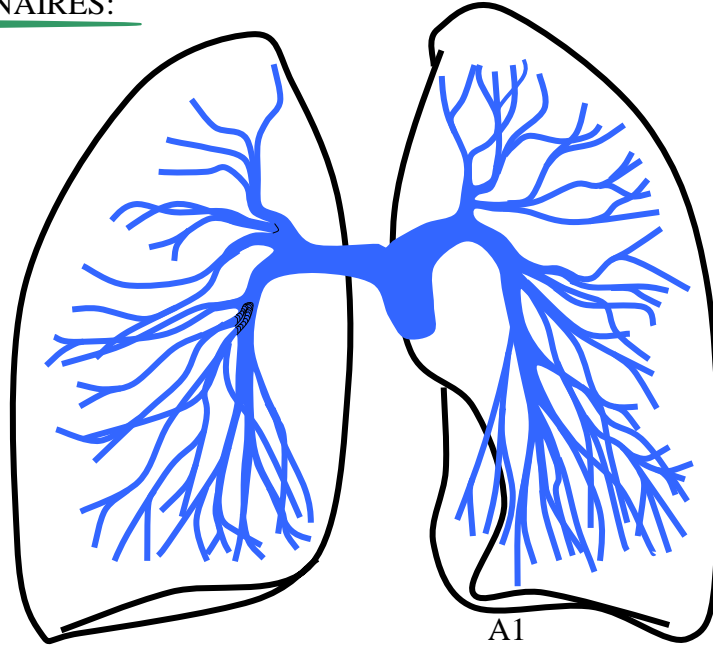


vue externe

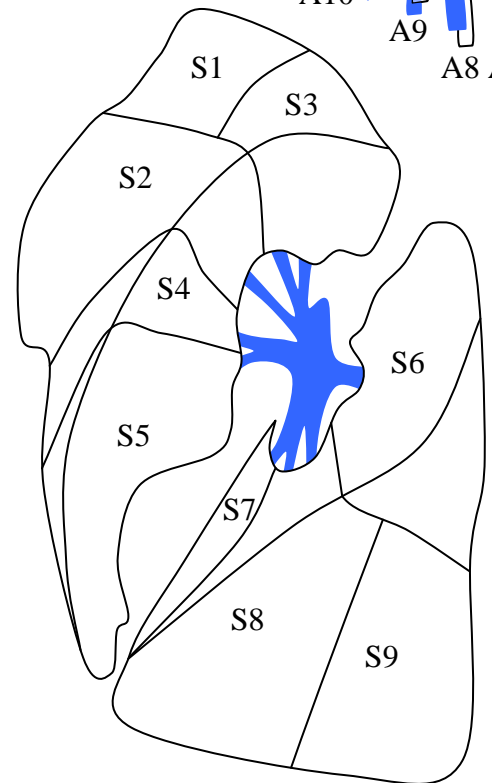
LES ARTERES PULMONAIRES:

DROIT

GAUCHE

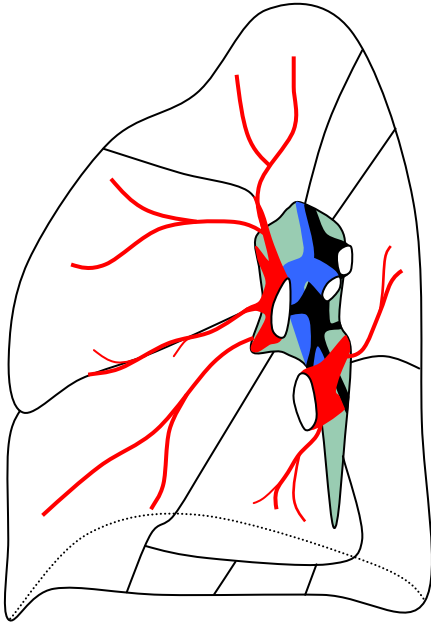


vue externe

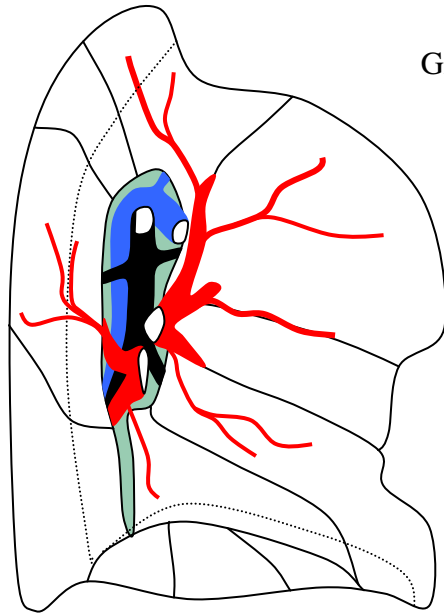


LES VEINES PULMONAIRES :

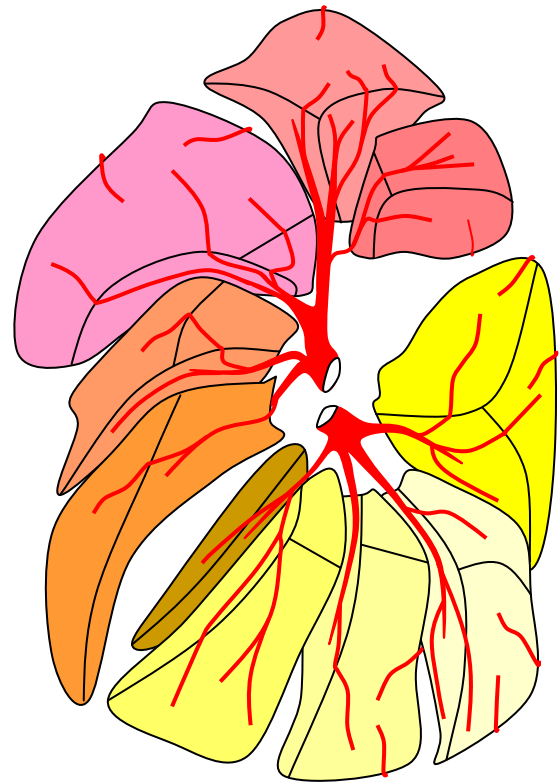
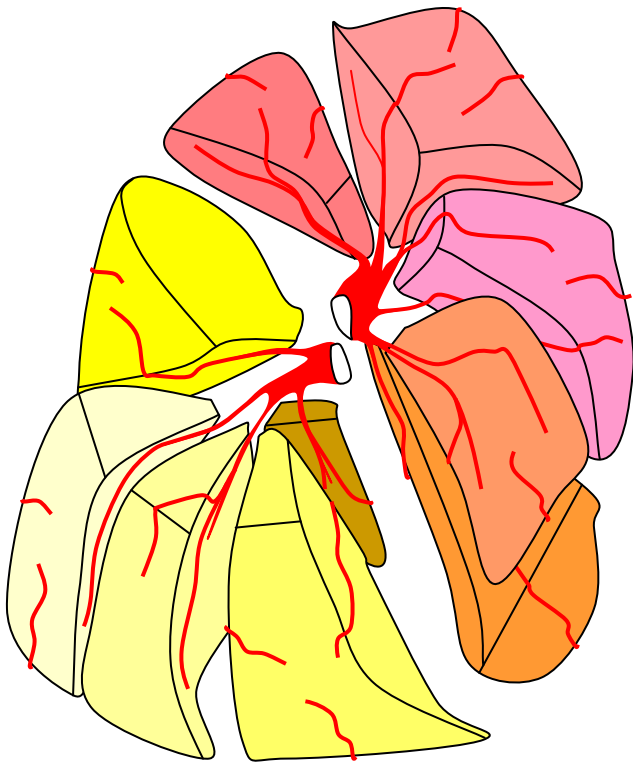
DROIT



GAUCHE

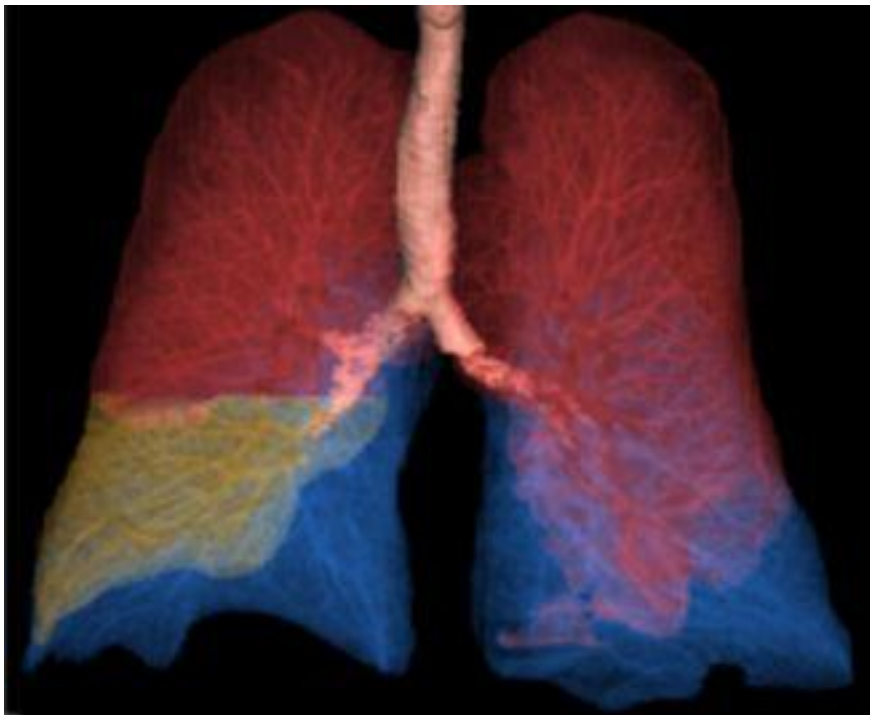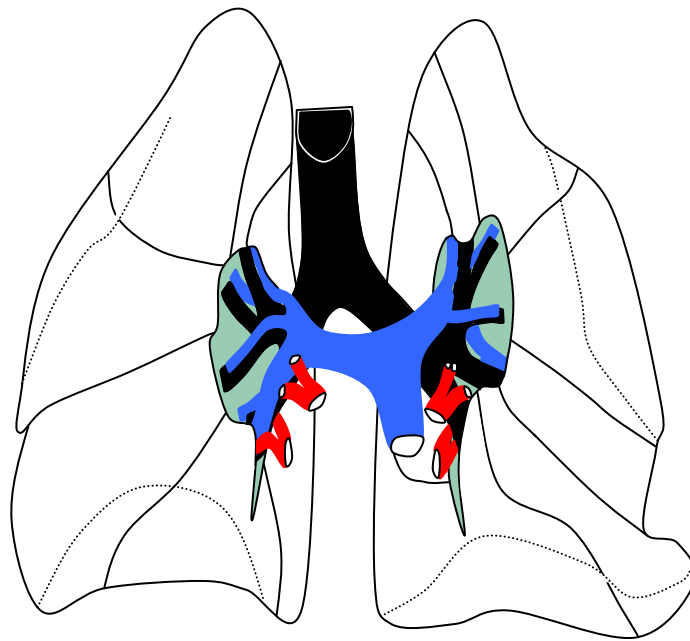


vue interne



vue externe

VUE GLOBALE :



Aspect tomodensitométrique de la segmentation, vue de face en VR.

